REVIEW ARTICLE

Edward W. Campion, M.D., *Editor*

Obliterative Bronchiolitis

Alan F. Barker, M.D., Anne Bergeron, M.D., Ph.D.,
William N. Rom, M.D., M.P.H., and Marshall I. Hertz, M.D.

From the Division of Pulmonary and Critical Care, Department of Medicine, Oregon Health and Science University, Portland (A.F.B.); Service de Pneumologie; Assistance Publique–Hôpitaux de Paris, Hôpital Saint Louis, Paris (A.B.); Division of Pulmonary and Critical Care Medicine, Department of Medicine, New York University School of Medicine, New York (W.N.R.); and Division of Pulmonary, Allergy, Critical Care, and Sleep Medicine, Department of Medicine, University of Minnesota, Minneapolis (M.I.H.). Address reprint requests to Dr. Barker at Pulmonary and Critical Care, UHN-67, Oregon Health and Science University, Portland, OR 97239, or at barkera@ohsu.edu.

N Engl J Med 2014;370:1820-8.
DOI: 10.1056/NEJMra1204664

The term "bronchiolitis obliterans" was historically used by pathologists to refer to two distinct patterns of small-airway disease. The first was characterized by intraluminal polyps in the small airways. It was subsequently named bronchiolitis obliterans with organizing pneumonia and, more recently, cryptogenic organizing pneumonia. The second pattern was characterized by subepithelial inflammatory and fibrotic narrowing of the bronchioles, which is now recognized as obliterative bronchiolitis or constrictive bronchiolitis.[1,2] To add to the confusion, physicians may use the term "bronchiolitis obliterans syndrome" to denote the occurrence of an obstructive ventilatory defect that occurs after transplantation (Table 1), particularly in patients who have undergone solid-organ or bone marrow transplantation. When a lung-biopsy specimen is available, examination shows that the obstructive lung defect is related to a pathological pattern of obliterative bronchiolitis. The clinical presentation of patients with obliterative bronchiolitis is characterized by progressive dyspnea and nonproductive cough over a period of weeks to months and abnormal pulmonary function that is frequently characterized by an obstructive airflow pattern. Computed tomography (CT) performed on expiration shows air trapping. This review focuses on several key issues: the recognition of obliterative bronchiolitis as an occupational disease, the frequent occurrence of the bronchiolitis obliterans syndrome after allogeneic hematopoietic stem-cell transplantation (HSCT) or lung transplantation, difficulties in establishing the diagnosis, and current therapeutic options.

PATHOGENESIS

The histopathological features of obliterative bronchiolitis suggest that injury and inflammation of small-airway epithelial cells and subepithelial structures lead to excessive fibroproliferation, which is due to aberrant tissue repair, including ineffective epithelial regeneration, in response to tissue injury (Fig. 1).[3] The diverse medical conditions and exposures that result in obliterative bronchiolitis suggest that it is a final common pathway, in which various insults can lead to similar microscopic, physiological, and clinical results. Although it has been recognized for more than 60 years that obliterative bronchiolitis develops in response to inhalation of toxic fumes and is associated with autoimmune disorders, little is known about its cellular and molecular pathogenesis.

The increasing frequency of obliterative bronchiolitis as a complication of HSCT and lung transplantation over the past 30 years has prompted studies contributing to our understanding of obliterative bronchiolitis that is not related to transplantation. Several sources of injury to the airway have been associated with the development of obliterative bronchiolitis, including viral respiratory infection, chronic gastroesophageal reflux, and long-standing exposure to high levels of air pollutants. Club cells (formerly called Clara cells), which promote regeneration of bronchiolar

epithelium, may be reduced in number or eliminated as a result of the inciting airway injury.[4-6] It has been suggested that polymorphisms, mostly in the genes of the innate immune system, are associated with the development of transplantation-related obliterative bronchiolitis.[7-9] The condition is attributed to an alloimmune reaction that is believed to represent chronic allograft rejection in patients who have undergone lung transplantation and chronic graft-versus-host disease (GVHD) in patients who have undergone allogeneic HSCT. Initially, the development of obliterative bronchiolitis after lung transplantation was assumed to be the result of direct T-cell–mediated injury of graft structures (i.e., chronic cellular rejection).[10] Indeed, acute cellular rejection, characterized by perivascular or peribronchial infiltration of activated lymphocytes into graft tissue, is a risk factor for obliterative bronchiolitis.[11] Studies have shown that the presence of circulating antibodies to donor HLA molecules (i.e., donor-specific antibodies) is also associated with the disorder, suggesting that antibody-mediated rejection has a causative role.[12,13] In addition, autoimmune responses to airway proteins, including those directed against collagen and K-alpha 1 tubulin, have been identified as having potential importance in the pathogenesis of obliterative bronchiolitis.[14-16] A direct autoimmune cause of the disorder was also suggested in patients with paraneoplastic pemphigus in whom airway-biopsy specimens showed acantholytic respiratory epithelial changes and the presence of the putative paraneoplastic autoantibodies directed against plakin.[17] In an animal model, donor B-cell alloantibody deposition and germinal-center formation were shown to be required for the development of obliterative bronchiolitis after allogeneic HSCT.[18] Finally, levels of several cytokines, chemokines, and other profibrotic factors have been shown to be elevated during the development of obliterative bronchiolitis associated with transplantation.[5,19-21]

Table 1. Disorders of the Bronchioles.

Overlapping or related constrictive disorders

Bronchiolitis obliterans: synonymous with obliterative bronchiolitis

Constrictive bronchiolitis: characterized by constrictive fibroproliferative narrowing of small-airway walls

Bronchiolitis obliterans syndrome: clinical manifestations of obliterative bronchiolitis in patients who have undergone lung transplantation or hematopoietic stem-cell transplantation

Other disorders

Panbronchiolitis: seen mainly in Asia; characterized by foamy macrophages in bronchiolar walls in upper and lower airways; thought to follow infection; responds well to macrolides

Follicular bronchiolitis: usually refers to constriction of bronchioles by surrounding lymphoid tissue; often associated with autoimmune disorders

Respiratory bronchiolitis–interstitial lung disease: uniformly associated with cigarette smoking; characterized by accumulation of macrophages with finely granular brown pigment in airway lumen and by desquamative interstitial pneumonia involving alveolar filling of pigment-laden macrophages; both respiratory bronchitis–interstitial lung disease and pneumonia may be reversible with smoking cessation

Bronchiolitis obliterans with organizing pneumonia (BOOP), also known as cryptogenic organizing pneumonia: clinically and histologically distinct from obliterative bronchiolitis; characterized by inflammatory process primarily involving alveolar ducts and interstitium and by proliferation of polypoid fibroblasts in airway lumen; sometimes occurs after bacterial pneumonia, but inciting insult often unknown; often responds to systemic glucocorticoids

Hypersensitivity pneumonitis: can be associated with small-airway narrowing due to poorly formed epithelial and subepithelial granuloma; clinical history is important in identifying the provoking antigen

CLINICAL DETECTION AND MONITORING

PULMONARY FUNCTION

In its most common presentation, obliterative bronchiolitis is characterized by the physiological features of respiratory obstruction. The major findings on spirometry are a normal, or slightly decreased, forced vital capacity (FVC), a reduced forced expiratory volume in 1 second (FEV_1), and a reduced ratio of FEV_1 to FVC, with a poor response to inhaled bronchodilators. Lung volumes indicate air trapping, with a normal total lung capacity and high residual volume. However, obstructive impairment is not universal. A subset of patients has normal results on spirometry, a restrictive pattern characterized by a low FVC and a normal FEV_1:FVC ratio, or a mixed pattern of obstruction and restriction. The diffusing capacity for carbon monoxide is initially normal but may decrease with disease progression. The extent to which oxygenation is impaired is highly variable, most likely because of the heterogeneous anatomical distribution of disease among affected patients.

A uniform definition of obliterative bronchiolitis after lung transplantation, which is based on changes in FEV_1, was established in 1993 and revised in 2002 (Table S1 in the Supplementary Appendix, available with the full text of this article at NEJM.org).[22] For patients who have under-

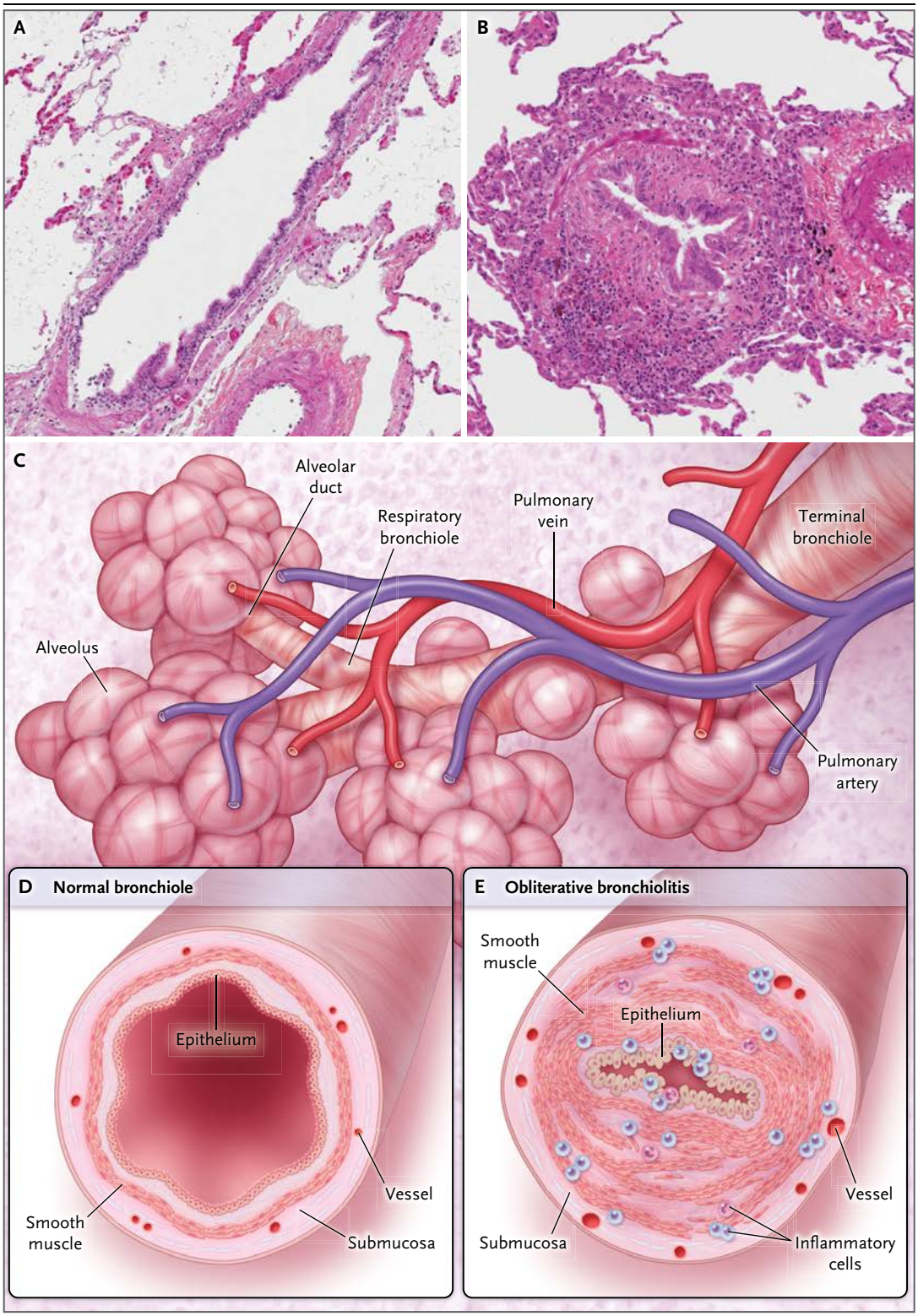

Figure 1 (facing page). Histologic and Schematic Views of Normal Bronchioles and Biopsy Specimen from a Patient with Obliterative Bronchiolitis after Allogeneic Hematopoietic Stem-Cell Transplantation.

Lung-biopsy specimens of a normal bronchiole and a bronchiole from a patient who received a diagnosis of obliterative bronchiolitis 8 months after undergoing allogeneic hematopoietic stem-cell transplantation are shown, respectively, in Panels A and B (hematoxylin and eosin). In Panel B, the bronchiolar wall is thickened by inflammatory fibrosis that is located between the epithelium and the smooth muscle. The airway lumen is narrowed. Panel C shows a normal bronchiole connecting to an alveolus. Panel D shows a cross section of a normal bronchiole, and Panel E shows a cross section of a bronchiole affected by obliterative bronchiolitis. The images in Panels A and B were provided by Dr. Véronique Meignin.

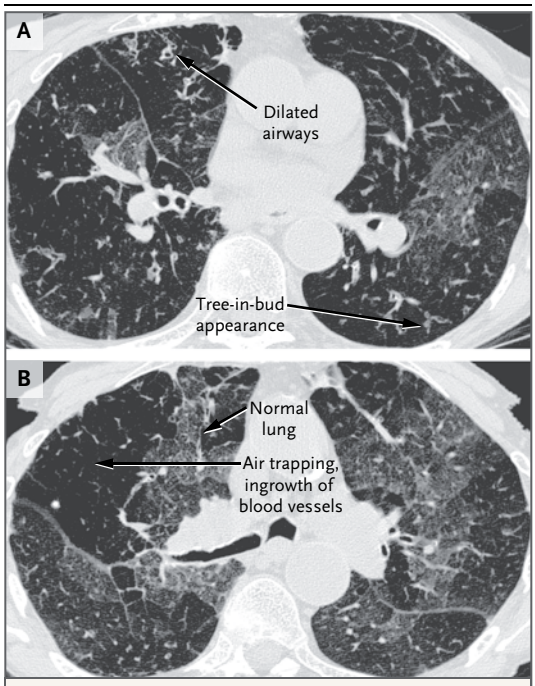

Figure 2. High-Resolution Computed Tomographic (HRCT) Images of the Lung from a Patient with Graft-versus-Host Disease and Advanced Obliterative Bronchiolitis.

In Panel A, an image obtained during inspiration reveals dilated airways and the tree-in-bud appearance of obstructed bronchioles. In Panel B, an image obtained during an expiratory breathhold shows patchy, hyperlucent areas between areas of normal lung tissue, which is characteristic of air trapping and is referred to as mosaic attenuation. Images provided by Dr. Srinivas Mummadi.

gone HSCT, a consensus definition has been established by the National Institutes of Health in its 2005 guidelines for chronic GVHD (Table S1 in the Supplementary Appendix). Although this definition has helped standardize the diagnosis of obliterative bronchiolitis after allogeneic HSCT, it neither identifies the disease at an early stage nor includes cases characterized by a normal FEV_1:FVC ratio and air trapping in the chest.[23] Therefore, a modification of these criteria has been proposed (Table S1 in the Supplementary Appendix).[24]

IMAGING

The plain chest radiograph is usually normal in patients with obliterative bronchiolitis, at least early in the disease process. Hyperinflation and increased linear or reticular markings of airway-wall thickening are suggestive but nonspecific findings. High-resolution CT (HRCT), performed near total lung capacity and near residual volume without the administration of contrast material, has become a definitive noninvasive test for obliterative bronchiolitis. Patchy areas of decreased lung density associated with reduced vascular caliber are identified on HRCT. This pattern has been referred to as mosaic perfusion or mosaic attenuation, in which areas of decreased attenuation that represent bronchial or bronchiolar air trapping are enhanced on expiratory HRCT scans (Fig. 2). In advanced cases, there may be dilatation and thickening of large airways, which are characteristic of bronchiectasis (Fig. 2). Expiratory CT scans may facilitate the early detection of obliterative bronchiolitis, since they may show air trapping before impairment can be detected on pulmonary-function tests.[25] A characteristic feature of the disease is the paucity of ground-glass opacities, which would be seen in pneumonia or organizing pneumonia.

ASSOCIATED CONDITIONS

AUTOIMMUNE DISORDERS

Among the autoimmune disorders, the frequency of obliterative bronchiolitis is the highest in patients with rheumatoid arthritis.[26] Obliterative bronchiolitis in rheumatoid arthritis was originally considered to be an adverse effect of medi-

cations, including penicillamine and gold. Its persistence despite reduced use of these drugs has led to the hypothesis that obliterative bronchiolitis may be more directly related to an autoimmune diathesis of rheumatoid arthritis and that treatment of the autoimmune disorder should contribute to the management of obliterative bronchiolitis.

EXPOSURE TO INHALATIONAL TOXINS

The earliest reported cases of obliterative bronchiolitis related to occupation occurred after exposures to sulfur dioxide and hydrogen sulfide, both of which are toxic to the eyes, skin, and respiratory tract and were used during World War I (1914–1918) and the Iran–Iraq War (1980–1988). Most such inhalations of toxic gases cause extensive damage, resulting in acute chemical pneumonitis followed by chest tightness, dyspnea, and massive hemoptysis, with fibrous exudates and granulation tissue in the bronchi and distal bronchioles that eventually lead to obliterative bronchiolitis. In an animal model, an exposure to chlorine, at 300 ppm, obliterated basal cells, preventing epithelial-cell regeneration and allowing inflammation, fibroblast infiltration, collagen deposition, and ingrowth of blood vessels, which led to lethal airway obstruction.[27] In humans, an exposure of 5 to 15 ppm may lead to moderate mucous-membrane injury. At an exposure of 40 to 60 ppm, lung injury and pneumonitis will occur.[28]

In the decade after the Iran–Iraq war, 34,000 Iranian soldiers and civilian survivors of exposure to sulfur mustard were evaluated. Skin blistering or vesicle formation and visual impairment and pain were common, with spirometric evidence of respiratory impairment in 43% of the study participants and severe impairment in 1%.[29] CT scans often revealed air trapping, bronchiectasis, thickening of bronchial walls, irregular and dilated airways, and mosaic attenuation, and the results of open-lung biopsies, performed in 15 study participants 17 to 18 years after exposure, showed obliterative bronchiolitis in 5 patients.[30,31] Peribronchial inflammation and fibrosis occur in pneumoconioses such as asbestosis and interstitial lung disease, especially in patients with hypersensitivity pneumonitis.[32,33]

In a recent study involving 80 soldiers who had served in Iraq or Afghanistan, 49 underwent thoracoscopic lung biopsies.[34] All 80 soldiers were referred for medical examination because of exercise-related dyspnea. The most common recognized exposures included proximity to a fire in a sulfur mine in Mosul in 2003, exposure to visually obscuring dust storms, exposure to incinerated solid and human waste in burning pits near living quarters, and exposure to combat smoke. Measures of cardiopulmonary function were significantly reduced in all affected soldiers as compared with those historically reported for healthy soldiers. The pathological findings revealed that 38 soldiers had obliterative bronchiolitis, which was diagnosed on the basis of bronchiolar luminal narrowing resulting from mural hypertrophy of smooth muscle and surrounding fibrous tissue. Deposition of peribronchial pigment was found in 37 soldiers, and the pigment contained polarizable material in 36 of the soldiers. Hypertensive-type arterial changes were seen in specimens obtained from 28 of 38 biopsies. No involvement of the large airways was reported.

The use of diacetyl (and related chemicals, including 2,3-pentanedione) in the manufacture of food flavorings has been reported as a cause of obliterative bronchiolitis. The first case reports included workers from popcorn-processing plants in Missouri and Nebraska that were producing a butter flavoring. All workers studied had new and otherwise unexplained severe airflow obstruction.[35] An investigation conducted by the National Institute for Occupational Safety and Health at one of the plants led to the identification of eight cases of obliterative bronchiolitis among former workers.[36] A survey of 87% of 135 workers at a popcorn-processing plant showed that those working most closely with diacetyl had dramatic increases in cough, dyspnea, and wheezing; physician-diagnosed obstructive lung disease; and spirometric evidence of airflow obstruction.[37] These reports have raised additional concerns because diacetyl is used in the manufacture of or is a component of various snack foods (e.g., buttered popcorn and chips), confections (e.g., candy), dairy products (e.g., butter and ice cream), baked goods, and coffee flavorings (Table 2).

Although the symptoms of exposure to toxic fumes may be nonspecific, management involves applying the principles of medical surveillance to workers and the workplace, including screening workers for pulmonary function; re-

moving workers from a potential or suspected source of exposure; conducting an epidemiologic investigation; monitoring the workplace and its surroundings, equipment, and any chemical additives used; and educating workers, health authorities, and industry. There is no curative treatment for obliterative bronchiolitis due to toxic inhalation, and various responses to therapy have been reported. Bronchodilating medication and inhaled glucocorticoids, oral *N*-acetylcysteine, and interferon gamma have been shown to improve both clinical symptoms and the results of pulmonary-function tests in patients exposed to mustard gas.[38-40] However, in nine workers at a popcorn-production plant who had obliterative bronchiolitis, treatment with oral glucocorticoids (in seven of the workers) or with glucocorticoids and cyclophosphamide (in two) did not improve pulmonary function.[36]

Table 2. Fume and Particulate Exposures Associated with Obliterative Bronchiolitis.

Toxin	Comment
Sulfur mustard	Used in chemical warfare; one of the earliest associations of an agent with the condition
Nitrogen oxides	Used in fertilizer production; probably involved in silo-filler's disease
Diacetyl and alpha-diketone substitutes	Used in the manufacture of microwave popcorn, roasted and flavored coffee, cookie dough, and food flavorings
Multiple chemicals and incinerator fly ash released during combustion	Often produced by uncontrolled fires
Papaverine, found in juice extracted from *Sauropus androgynus,* or katuk	Juice extracted from this leafy plant may assist in weight loss; respiratory symptoms develop several weeks after ingestion
Fiberglass	Used in the fabrication of certain structural materials (e.g., for boats or automobile bodies)

POSTINFECTIOUS OBLITERATIVE BRONCHIOLITIS

Postinfectious obliterative bronchiolitis has been described, primarily in children, after infection with adenovirus, measles virus, or mycoplasma. In view of the high incidence of these infections, the development of permanent airway obstruction can be assumed to be quite unusual. The clinical disease may evolve for months to years after the initial pneumonia or severe respiratory illness.[41,42]

OBLITERATIVE BRONCHIOLITIS AFTER HSCT

Obliterative bronchiolitis is the primary noninfectious pulmonary complication in patients who undergo allogeneic HSCT. The condition typically develops within 2 years after transplantation, but it may occur several years afterward. The incidence of this serious and potentially fatal complication ranges from 5.5% in the overall population of patients who have undergone allogeneic HSCT to 14% in the subpopulation of patients with extrathoracic chronic GVHD.[43] Numerous clinical risk factors for obliterative bronchiolitis have been identified in retrospective studies, although there have been some conflicting results; these include older age of donor or recipient, greater degree of HLA mismatch, presence of gastroesophageal reflux, decreased gamma globulin levels, a busulfan-based conditioning regimen, GVHD prophylaxis, underlying hematologic disease, tobacco use, acute GVHD, and transplant type.[43,44] Epidemiologic studies have shown an association between the development of obliterative bronchiolitis and the presence of active chronic GVHD, which might suggest that obliterative bronchiolitis is a form of chronic GVHD of the lung. The recent increase in the use of peripheral-blood stem cells is associated with an increased risk of obliterative bronchiolitis.[45] Furthermore, patients in whom respiratory syncytial virus or parainfluenza virus infection develops within the first 100 days after HSCT are at increased risk for obliterative bronchiolitis in the year after transplantation.[46]

OBLITERATIVE BRONCHIOLITIS AFTER LUNG TRANSPLANTATION

Many diseases associated with obliterative bronchiolitis have been identified, including acute cellular rejection, development of donor-specific anti-HLA antibodies, gastroesophageal reflux disease with recurrent microaspiration and macroaspiration, and respiratory viral infections. In patients who have undergone lung transplantation, there is the added complication of microvascular insufficiency in the small airways of the transplanted lung, which presumably occurs because the supply of blood to the bronchial arteries is interrupted during transplantation. This disruption may lead to defective airway repair if there is subsequent immune or nonimmune injury.[47,48] Thus, as compared with normal lungs, transplanted lungs are more susceptible to alloimmune immunologic insults and to airway injury,

and they have a more limited regenerative capacity. Thus, it should not be surprising that obliterative bronchiolitis affects most long-term survivors of lung transplantation, among whom the 10-year probability of remaining free of the disease is less than 30%.[49,50]

Current immunosuppressive regimens used after lung transplantation generally include calcineurin inhibitors (cyclosporine or tacrolimus), purine synthesis inhibitors (azathioprine or mycophenolate mofetil) and glucocorticoids. A recent randomized trial showed that lung-transplant recipients treated with tacrolimus had a lower incidence of obliterative bronchiolitis than did those treated with cyclosporine, although there was no significant difference in survival rates.[51] A randomized trial comparing everolimus (a mammalian target of rapamycin [mTOR] inhibitor) with azathioprine in lung-transplant recipients treated with cyclosporine and prednisone showed a modest decrease in the rate of loss of lung function in the group treated with everolimus.[52]

A double-blind, randomized controlled trial of azithromycin versus placebo in lung-transplant recipients showed a decreased incidence of the bronchiolitis obliterans syndrome and an improved rate of syndrome-free survival in treated patients.[53] Other trials of macrolides are in progress, with final results pending.

TREATMENT OF OBLITERATIVE BRONCHIOLITIS AFTER HSCT OR LUNG TRANSPLANTATION

For patients with bronchiolitis obliterans who have undergone HSCT or lung transplantation, the current treatment consists primarily of increasing immunosuppression by changing medications within therapeutic classes, adding medications, or administering other immune-modulating therapies. Several immunosuppressive medications and immune-modulating treatments have been reported to stabilize pulmonary function in patients with the bronchiolitis obliterans syndrome (Table S2 in the Supplementary Appendix). Other, potentially less toxic treatment strategies have emerged, including the administration of low-dose macrolide antibiotics, leukotriene-receptor antagonists, and combinations of inhaled bronchodilators and glucocorticoids (Table S2 in the Supplementary Appendix). Several factors complicate the interpretation of these studies. First, the evidence for several therapies is based on small retrospective series. Second, in studies evaluating the treatment of obliterative bronchiolitis after HSCT, treatment responses have been poorly defined because the primary focus of the studies was GVHD, not specifically obliterative bronchiolitis. In addition, for most of the published studies, the findings are difficult to interpret because the severity of obliterative bronchiolitis varied among the study patients.

The disease probably has various clinical phenotypes, as was suggested by the different responses to therapy among patients in whom obliterative bronchiolitis developed after lung transplantation.[54] As a case in point, azithromycin has resulted in improved pulmonary function in approximately 50% of lung-transplant recipients with obliterative bronchiolitis.[55,56] A retrospective analysis indicated that the administration of azithromycin in patients with obliterative bronchiolitis after lung transplantation is associated with improved survival.[57] The beneficial effects of azithromycin appear to be mediated by a decrease in airway neutrophilia and related cytokine activation.[58] For end-stage obliterative bronchiolitis, lung transplantation (in the case of patients who have undergone HSCT) or repeat lung transplantation (in the case of those who have undergone a first lung transplantation) is accepted as a therapeutic option for carefully selected patients.

OUTCOME AND PROGNOSIS

The natural history of obliterative bronchiolitis is highly variable and cannot be predicted in individual patients. The earliest reported cases of occupational obliterative bronchiolitis were recognized because of acute, intense toxic exposure. More recent examples suggest a prolonged exposure that can occasionally lead to severe respiratory insufficiency.[36,59] The incidence of obstructive abnormalities on spirometry was shown to increase with increasing cumulative exposure to airborne flavoring chemicals.[59] Increased mortality from respiratory disease has recently been found at a microwave popcorn-production facility where there was a risk of obliterative bronchiolitis among workers, especially those employed before the company reduced exposure to diacetyl.[60] In fact, obliterative bronchiolitis is generally nonprogressive once exposure ceases.[36]

Transplant-related obliterative bronchiolitis has been associated with an increased risk of death,

especially when it develops soon after transplantation.[23,50] Although transplant-related obliterative bronchiolitis is generally characterized by a relentless deterioration in pulmonary function, FEV_1 stabilizes in a subset of patients.[22,23,59]

Dr. Bergeron reports receiving lecture fees from Genzyme, Bristol-Myers Squibb, Pfizer, Gilead, MSD, and Chiesi, travel support from MSD, Chiesi, and VitalAire, and active and placebo treatment units from AstraZeneca for a trial funded by the French Ministry of Health; and Dr. Hertz, receiving grant support from APT Pharmaceuticals and consulting fees from Alnylam and Novartis. No other potential conflict of interest relevant to this article was reported.

Disclosure forms provided by the authors are available with the full text of this article at NEJM.org.

We thank Drs. Jason Chien and Regis Peffault de Latour for their thoughtful reviews of an earlier version of the manuscript.

REFERENCES

1. Ryu JH, Myers JL, Swensen SJ. Bronchiolar disorders. Am J Respir Crit Care Med 2003;168:1277-92.

2. Colby TV, Epler GR, Gruden JF. Bronchiolar disorders. In: Crapo JD, ed. Atlas of pulmonary medicine. 4th ed. Philadelphia: Current Medicine Group/Springer, 2008: 69-84.

3. Yousem SA, Berry GJ, Cagle PT, et al. Revision of the 1990 working formulation for the classification of pulmonary allograft rejection: Lung Rejection Study Group. J Heart Lung Transplant 1996;15:1-15.

4. Palmer SM, Flake GP, Kelly FL, et al. Severe airway epithelial injury, aberrant repair and bronchiolitis obliterans develops after diacetyl instillation in rats. PLoS One 2011;25(6):e17644.

5. Panoskaltsis-Mortari A, Tram KV, Price AP, Wendt CH, Blazar BR. A new murine model for bronchiolitis obliterans post-bone marrow transplant. Am J Respir Crit Care Med 2007;176:713-23.

6. Kelly FL, Kennedy VE, Jain R, et al. Epithelial Clara cell injury occurs in bronchiolitis obliterans syndrome after human lung transplantation. Am J Transplant 2012;12:3076-84.

7. Kastelijn EA, van Moorsel CH, Rijkers GT, et al. Polymorphisms in innate immunity genes associated with development of bronchiolitis obliterans after lung transplantation. J Heart Lung Transplant 2010;29:665-71.

8. Chien JW, Zhao LP, Hansen JA, Fan WH, Parimon T, Clark JG. Genetic variation in bactericidal/permeability-increasing protein influences the risk of developing rapid airflow decline after hematopoietic cell transplantation. Blood 2006;107:2200-7.

9. Hildebrandt GC, Granell M, Urbano-Ispizua A, et al. Recipient NOD2/CARD15 variants: a novel independent risk factor for the development of bronchiolitis obliterans after allogeneic stem cell transplantation. Biol Blood Marrow Transplant 2008; 14:67-74.

10. Verleden GM, Dupont LJ, Van Raemdonck DE. Is it bronchiolitis obliterans syndrome or is it chronic rejection: a reappraisal? Eur Respir J 2005;25:221-4.

11. Finlen Copeland CA, Snyder LD, Zaas DW, Turbyfill WJ, Davis WA, Palmer SM. Survival after bronchiolitis obliterans syndrome among bilateral lung transplant recipients. Am J Respir Crit Care Med 2010; 182:784-9.

12. Palmer SM, Davis RD, Hadjiliadis D, et al. Development of an antibody specific to major histocompatibility antigens detectable by flow cytometry after lung transplant is associated with bronchiolitis obliterans syndrome. Transplantation 2002;74:799-804.

13. Hadjiliadis D, Chaparro C, Reinsmoen NL, et al. Pre-transplant panel reactive antibody in lung transplant recipients is associated with significantly worse post-transplant survival in a multicenter study. J Heart Lung Transplant 2005;24:Suppl: S249-S254.

14. Wilkes DS. Autoantibody formation in human and rat studies of chronic rejection and primary graft dysfunction. Semin Immunol 2012;24:131-5.

15. Seetharam A, Tiriveedhi V, Mohanakumar T. Alloimmunity and autoimmunity in chronic rejection. Curr Opin Organ Transplant 2010;15:531-6.

16. Hachem RR, Tiriveedhi V, Patterson GA, Aloush A, Trulock EP, Mohanakumar T. Antibodies to K-α 1 tubulin and collagen V are associated with chronic rejection after lung transplantation. Am J Transplant 2012;12:2164-71.

17. Nousari HC, Deterding R, Wojtczack H, et al. The mechanism of respiratory failure in paraneoplastic pemphigus. N Engl J Med 1999;340:1406-10.

18. Srinivasan M, Flynn R, Price A, et al. Donor B-cell alloantibody deposition and germinal center formation are required for the development of murine chronic GVHD and bronchiolitis obliterans. Blood 2012;119:1570-80.

19. Weinberger B, Laskin JD, Sunil VR, Sinko PJ, Heck DE, Laskin DL. Sulfur mustard-induced pulmonary injury: therapeutic approaches to mitigating toxicity. Pulm Pharmacol Ther 2011;24:92-9.

20. Zarin AA, Behmanesh M, Tavallaei M, Shohrati M, Ghanei M. Overexpression of transforming growth factor (TGF)-beta1 and TGF-beta3 genes in lung of toxic-inhaled patients. Exp Lung Res 2010;36: 284-91.

21. Weigt SS, Derhovanessian A, Liao E, et al. CXCR3 chemokine ligands during respiratory viral infections predict lung allograft dysfunction. Am J Transplant 2012; 12:477-84.

22. Estenne M, Maurer JR, Boehler A, et al. Bronchiolitis obliterans syndrome 2001: an update of the diagnostic criteria. J Heart Lung Transplant 2002;21:297-310.

23. Bergeron A, Godet C, Chevret S, et al. Bronchiolitis obliterans syndrome after allogeneic hematopoietic SCT: phenotypes and prognosis. Bone Marrow Transplant 2013;48:819-24.

24. Chien JW, Duncan S, Williams KM, Pavletic SZ. Bronchiolitis obliterans syndrome after allogeneic hematopoietic stem cell transplantation — an increasingly recognized manifestation of chronic graft-versus-host disease. Biol Blood Marrow Transplant 2010;16:Suppl:S106-S114.

25. Bankier AA, Van Muylem A, Knoop C, Estenne M, Gevenois PA. Bronchiolitis obliterans syndrome in heart-lung transplant recipients: diagnosis with expiratory CT. Radiology 2001;218:533-9.

26. Perez T, Remy-Jardin M, Cortet B. Airways involvement in rheumatoid arthritis: clinical, functional, and HRCT findings. Am J Respir Crit Care Med 1998;157:1658-65.

27. O'Koren EG, Hogan BL, Gunn MD. Loss of basal cells precedes bronchiolitis obliterans-like pathological changes in a murine model of chlorine gas inhalation. Am J Respir Cell Mol Biol 2013;49:788-97.

28. White CW, Martin JG. Chlorine gas inhalation: human clinical evidence of toxicity and experience in animal models. Proc Am Thorac Soc 2010;7:257-63.

29. Khateri S, Ghanei M, Keshavarz S, Soroush M, Haines D. Incidence of lung, eye, and skin lesions as late complications in 34,000 Iranians with wartime exposure to mustard agent. J Occup Environ Med 2003;45:1136-43.

30. Ghanei M, Mokhtari M, Mohammad MM, Aslani J. Bronchiolitis obliterans following exposure to sulfur mustard: chest high resolution computed tomography. Eur J Radiol 2004;52:164-9.

31. Ghanei M, Tazelaar HD, Chilosi M, et al. An international collaborative pathologic study of surgical lung biopsies from mustard gas-exposed patients. Respir Med 2008;102:825-30.

32. Wright JL, Churg A. Severe diffuse small airways abnormalities in long term chrysotile asbestos miners. Br J Ind Med 1985;42:556-9.

33. Burgel PR, Bergeron A, de Blic J, et al.

Small airways diseases, excluding asthma and COPD: an overview. Eur Respir Rev 2013;22:131-47.
34. King MS, Eisenberg R, Newman JH, et al. Constrictive bronchiolitis in soldiers returning from Iraq and Afghanistan. N Engl J Med 2011;365:222-30. [Erratum, N Engl J Med 2011;365:1749.]
35. Parmet AJ, Von Essen S. Rapidly progressive, fixed airway obstructive disease in popcorn workers: a new occupational pulmonary illness? J Occup Environ Med 2002;44:216-8.
36. Akpinar-Elci M, Travis WD, Lynch DA, Kreiss K. Bronchiolitis obliterans syndrome in popcorn production plant workers. Eur Respir J 2004;24:298-302.
37. Kreiss K, Gomaa A, Kullman G, Fedan K, Simoes EJ, Enright PL. Clinical bronchiolitis obliterans in workers at a microwave-popcorn plant. N Engl J Med 2002;347:330-8.
38. Ghanei M, Shohrati M, Harandi AA, et al. Inhaled corticosteroids and long-acting beta 2-agonists in treatment of patients with chronic bronchiolitis following exposure to sulfur mustard. Inhal Toxicol 2007;19:889-94.
39. Shohrati M, Aslani J, Eshraghi M, Alaedini F, Ghanei M. Therapeutics effect of N-acetyl cysteine on mustard gas exposed patients: evaluating clinical aspect in patients with impaired pulmonary function test. Respir Med 2008;102:443-8.
40. Panahi Y, Ghanei M, Vahedi E, et al. Effect of recombinant human IFNγ in the treatment of chronic pulmonary complications due to sulfur mustard intoxication. J Immunotoxicol 2014;11:72-7.
41. Chang AB, Masel JP, Masters B. Post-infectious bronchiolitis obliterans: clinical, radiological and pulmonary function sequelae. Pediatr Radiol 1998;28:23-9.
42. Kim CK, Kim SW, Kim JS, et al. Bronchiolitis obliterans in the 1990s in Korea and the United States. Chest 2001;120:1101-6.
43. Au BK, Au MA, Chien JW. Bronchiolitis obliterans syndrome epidemiology after allogeneic hematopoietic cell transplantation. Biol Blood Marrow Transplant 2011;17:1072-8.
44. Dudek AZ, Mahaseth H, DeFor TE, Weisdorf DJ. Bronchiolitis obliterans in chronic graft-versus-host disease: analysis of risk factors and treatment outcomes. Biol Blood Marrow Transplant 2003;9:657-66.
45. Alam N, Marras TK, Atenafu EG, et al. Allogeneic peripheral blood stem cell transplantation significantly increases risk of chronic graft-versus-host disease of lung compared with bone marrow transplantation. Biol Blood Marrow Transplant 2012;18:1905-10.
46. Erard V, Chien JW, Kim HW, et al. Airflow decline after myeloablative allogeneic hematopoietic cell transplantation: the role of community respiratory viruses. J Infect Dis 2006;193:1619-25.
47. Dhillon GS, Zamora MR, Roos JE, et al. Lung transplant airway hypoxia: a diathesis to fibrosis? Am J Respir Crit Care Med 2010;182:230-6.
48. Pettersson GB, Budev M. The role of ischemia in postlung transplantation complications. Curr Opin Organ Transplant 2010;15:549-51.
49. Benden C, Edwards LB, Kucheryavaya AY, et al. The Registry of the International Society for Heart and Lung Transplantation: fifteenth pediatric lung and heart-lung transplantation report — 2012. J Heart Lung Transplant 2012;31:1087-95.
50. Christie JD, Edwards LB, Kucheryavaya AY, et al. The Registry of the International Society for Heart and Lung Transplantation: 29th adult lung and heart-lung transplant report — 2012. J Heart Lung Transplant 2012;31:1073-86.
51. Treede H, Glanville AR, Klepetko W, et al. Tacrolimus and cyclosporine have differential effects on the risk of development of bronchiolitis obliterans syndrome: results of a prospective, randomized international trial in lung transplantation. J Heart Lung Transplant 2012;31:797-804.
52. Snell GI, Valentine VG, Vitulo P, et al. Everolimus versus azathioprine in maintenance lung transplant recipients: an international, randomized, double-blind clinical trial. Am J Transplant 2006;6:169-77.
53. Vos R, Vanaudenaerde BM, Verleden SE, et al. A randomised controlled trial of azithromycin to prevent chronic rejection after lung transplantation. Eur Respir J 2011;37:164-72.
54. Vanaudenaerde BM, Meyts I, Vos R, et al. A dichotomy in bronchiolitis obliterans syndrome after lung transplantation revealed by azithromycin therapy. Eur Respir J 2008;32:832-43.
55. Gerhardt SG, McDyer JF, Girgis RE, Conte JV, Yang SC, Orens JB. Maintenance azithromycin therapy for bronchiolitis obliterans syndrome: results of a pilot study. Am J Respir Crit Care Med 2003;168:121-5.
56. Federica M, Nadia S, Monica M, et al. Clinical and immunological evaluation of 12-month azithromycin therapy in chronic lung allograft rejection. Clin Transplant 2011;25:E381-9.
57. Jain R, Hachem RR, Morrell MR, et al. Azithromycin is associated with increased survival in lung transplant recipients with bronchiolitis obliterans syndrome. J Heart Lung Transplant 2010;29:531-7.
58. Vos R, Vanaudenaerde BM, Verleden SE, et al. Anti-inflammatory and immunomodulatory properties of azithromycin involved in treatment and prevention of chronic lung allograft rejection. Transplantation 2012;94:101-9.
59. From the Centers for Disease Control and Prevention: fixed obstructive lung disease in workers at a microwave popcorn factory — Missouri, 2000-2002. JAMA 2002;287:2939-40.
60. Halldin CN, Suarthana E, Fedan KB, Lo YC, Turabelidze G, Kreiss K. Increased respiratory disease mortality at a microwave popcorn production facility with worker risk of bronchiolitis obliterans. PLoS One 2013;8(2):e57935.