Malignant germ cell tumor: Yolk sac tumor with extensive metastases

Noelle Tran, DO PGY2; Hala Alsalhi, DO PGY2; Rebecca McFall, MD
Department of Pediatrics, Advocate Children's Hospital – Oak Lawn

Advocate Children's Hospital
Tomorrow starts today.

Introduction

Abdominal masses may often be found incidentally by parents or pediatricians on exam. Generally, abdominal masses can be caught early in the outpatient setting. Sometimes patients may be asymptomatic or they may present in many ways that are not obvious like fever, hematuria, or even hypertension. However, given the pandemic, diagnosing abdominal masses has become more difficult due to the transition to telehealth visits. Abdominal masses can range from benign to neoplastic and often come from organs in the intra-abdominal cavity. The age of the patient can help guide physicians into the work up for the abdominal mass.

Objective

- Review approach to evaluating an abdominal mass and compose a differential diagnosis for an abdominal mass
- Show initial management of malignant germ cell tumor
- Review tumor lysis syndrome and discuss treatment

Differential diagnosis

Given the patient's age, initial differential diagnosis for an abdominal mass would most commonly derive from renal, intraabdominal, or pelvic etiology. After obtaining the images and speaking to our Hematology and oncology team, the differential was narrowed down to Hogkin's Lymphomas, Sarcomas like Ewings or Osteosarcoma, Germ cell tumor, and non-Hodgkin's lymphoma.

Case Description

D.E. is a previously healthy 17-year-old female who presented with two months of right hip pain and a week of increased abdominal distention. She was seen initially one month prior to admission via telehealth with her primary pediatrician who prescribed steroids and ibuprofen. Symptoms did not improve, and she began to develop abdominal distension, night sweats, and a 5 pound weight loss. She was seen by a massage therapist who palpated an abdominal mass and recommended going to the ED to be evaluated a physician. When she arrived to the ED, she was tachycardic, tachypneic, and hypertensive. On physical exam, she had decreased strength of her right lower extremity, swelling of her right hip and buttock with 1+ pitting edema. On her abdominal exam, her abdomen was distended and firm to palpation. CT abdomen performed that showed a large abdominopelvic mass measuring 21 x 19 x 12cm with metastasis to her lungs, liver, right acetabulum, pelvis, ribs, and left humeral head. Hematology and oncology team consulted and recommended obtaining AFP, which was 203,785, making germ cell tumor likely. US guided fine needle aspiration confirmed yolk sac tumor. Patient was evaluated by gynecology oncology team who felt that D.E. was not a candidate for surgical resection due to the size of the mass. They recommend chemotherapy to help reduce the size and possible resection in the future. Patient underwent a research study, AGCT 1532, and was randomized into Arm B, where she received bleomycin, etoposide, and cisplatin over a compressed two-week course vs the standard three-week course. Germ cell tumor is a rapidly growing tumor that may respond well to frequent intense cycles, and studies show improved outcomes with upfront therapy that will reduce need for later, more toxic therapy.

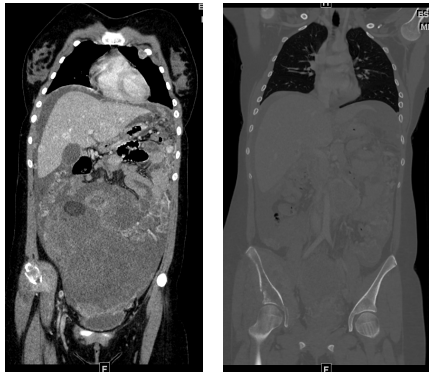

Figure 1. Large abdominopelvic mass measuring 21 x 19 x 12 cm on the left. On the left, there is a Pelvic XR comminuted displaced fracture of acetabulum

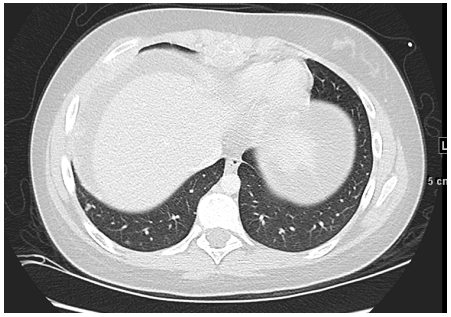

Figure 2. Enlarged liver, metases, abdominopelvic fluid, mass suggestive of presence of totipotential mesenchymal neoplasm

Case Description Cont'd

Her course was complicated by tumor lysis syndrome. She was given fluids 1.5 times maintenance fluids with no potassium. She also received Allopurinol and Rasburicase. Interestingly, tumor lysis is more commonly seen in leukemia or lymphomas, and rarely solid tumors. However, metastatic germ cell tumors can result in tumor lysis syndrome. Her tumor lysis improved following treatment. D.E. completed her chemotherapy and her AFP down trended at discharge. She underwent vigorous therapy with physical therapy and see by orthopedic oncology and gynecology oncology outpatient.

Discussion/Conclusions

- Examine patient when symptoms are not improving, especially important during the pandemic since many visits are now via telehealth
- Abdominal mass differential consider flank masses, GI masses, pelvic masses, malignancy, with the being most common being flank masses for adolescents
- TLS is an oncological emergency that causes metabolic abnormalities that can lead to renal failure, seizures, and dysrhythmia.
- Treatment for GCT remains the same however currently being studied about compressing treatment duration to two weeks

References

Russell, T. B., & Kram, D. E. (2020). Tumor Lysis Syndrome. *Pediatrics in Review*, *41*(1), 20-26. doi:10.1542/pir.2018-0243

Frazier, A. L., Hale, J. P., Rodriguez-Galindo, C., Ding, H., Olson, T., Murray, M. J., ... Nicholson, J. C. (2015). Revised Risk Classification for Pediatric Extracranial Germ Cell Tumors Based on 25 Years of Clinical Trial Data From the United Kingdom and United States. *Journal of Clinical Oncology*, *33*(2), 195-201. doi:10.1200/jco.2014.58.3369

Cairo, M. S., Coiffier, B., Reiter, A., & Younes, A. (2010). Recommendations for the evaluation of risk and prophylaxis of tumour lysis syndrome (TLS) in adults and children with malignant diseases: An expert TLS panel consensus. *British Journal of Haematology*, *149*(4), 578-586. doi:10.1111/j.1365-2141.2010.08148.x

Higdon M.L, Atkinson O.J, Lawrence K.V. Oncologic Emergencies: Recognition and Initial Management. *Am Fam Physician*. 2018;97(11):741-748.

Gow, K. W. (2012). *Abdominal Masses of Childhood*. Lecture presented at Standardized Toolbox of Education for Pediatric Surgery.