Advocate Christ Medical Center

UIC

Myocardial Infarction with Nonobstructive Coronary Arteries

A Paradigm Shift

Sabaa Ahmed, D.O., Sheraz Hussain, M.D., Luay Rifai, M.D.
Advocate Christ Medical Center, Oak Lawn, IL

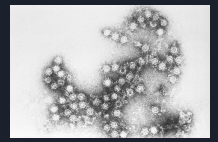

Background:

When thinking about myocardial infarctions, one typically thinks of obstructed coronary arteries leading to lack of perfusion to the myocardial tissue. However, this particular patient's presentation and ultimate findings served as a paradigm shift in modern-day cardiology.

Case Presentation:

This patient complained of back pain and headaches upon arrival. She did not report any chest discomfort or shortness of breath. Initial vitals were normal including blood pressure in both arms.

Initial EKG in the emergency room revealed mild ST elevations in lateral leads I and aVL, concerning for an acute ST elevation myocardial infarction.

After obtaining the initial EKG concerning for ST elevation myocardial infarction, repeat EKG was done and revealed worsening of ST elevation. Initial labs showed serial elevations of troponin up to 81. The patient was urgently taken to cardiac Cath lab and underwent coronary angiogram. Coronary angiography did not reveal any evidence of coronary artery disease with TIMI-3 flow in all vessels. Left ventriculogram was then done, showing an ejection fraction of 60%. Thereafter, another repeat EKG was done, which showed persistent lateral ST elevations.

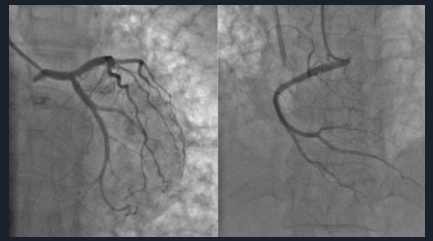

Myocardial biopsy however did show concern for lymphoplasmacytic interstitial infiltrate and serology came back positive for coxsackie B virus.

Discussion:

MINOCA occurs in approximately 5-6% of all diagnosed cases of acute myocardial infarction. It typically occurs in females without history of hyperlipidemia, and tends to be present in younger age groups. By definition, MINOCA must occur in patients without obstructive coronary lesions greater than 50%, which is determined by coronary angiography. It is of utmost importance that other overt causes for elevated troponin and nonischemic causes for myocyte injury are further investigated as well. Although it is understood that there have been no randomized trials or prospective studies conducted on MINOCA thus far, it is still recommended that if there is evidence of atherosclerosis in these patients, it should be treated aggressively. The underlying cause of MINOCA also plays a vital role in directing treatment. As with our patient, who was treated with calcium channel blockers, secondary to coronary vasospasm.