

# Staged Open Reduction Internal Fixation vs. External Fixation with Limited Internal Fixation of Moderate to Severe Pilon Fractures: A Meta-analysis Comparing Postoperative Results

Daniel Ryan, DPM; Robert Burdi, DPM; John Grady, DPM

Department of Podiatry, Advocate Christ Medical Center

Advocate  
Christ Medical Center  
Tomorrow starts today™



## Statement of purpose:

Pilon fractures are difficult to treat due to the high mechanism of injury and the usual extensive damage to the soft tissue envelope. Staged open reduction with internal fixation (ORIF) has been the gold standard for treating these fractures, allowing time for soft tissue inflammation to subside. Literature associates this method with high rates of complications. External fixation with limited internal fixation (EFLIF) has been advocated as an alternative due to the ability to restore anatomy while reducing risk of postoperative complications. These techniques have long been debated in the literature with no general consensus. The aim of this meta-analysis is to investigate the postoperative complications as well as clinical and functional outcomes in the management of severe pilon fractures between staged ORIF and EFLIF

## Methodology:

- Search Strategy:
  - The PubMed, MEDLINE, and Cochrane Library databases were searched for the following criteria: "internal fixation," "open reduction internal fixation," "ORIF," "staged ORIF," "staged open reduction internal fixation," "external fixation," "ExFix," "EFLIF," "LIFE," "external fixation limited internal fixation," "pilon fracture," and "tibial plafond fracture."
  - The databases were searched for eligible articles that were published on or after January 1st, 2006.
  - Articles were reviewed for inclusion/ exclusion by two authors (DR & DB)
- Inclusion:
  - Published on or after January 1<sup>st</sup>, 2006
  - English language
  - Rüedi-Allgöwer Types 2 & 3 fracture
  - AO/OTA Type 43B & 43C
  - Comparative study investigating ORIF versus EFLIF
- Exclusion:
  - Review articles and cadaveric studies
  - Studies evaluating patients under age 18 years
  - Studies with level of evidence 5 or a case study
  - Studies with less than 12 months of follow-up
  - Studies evaluating pathological fractures

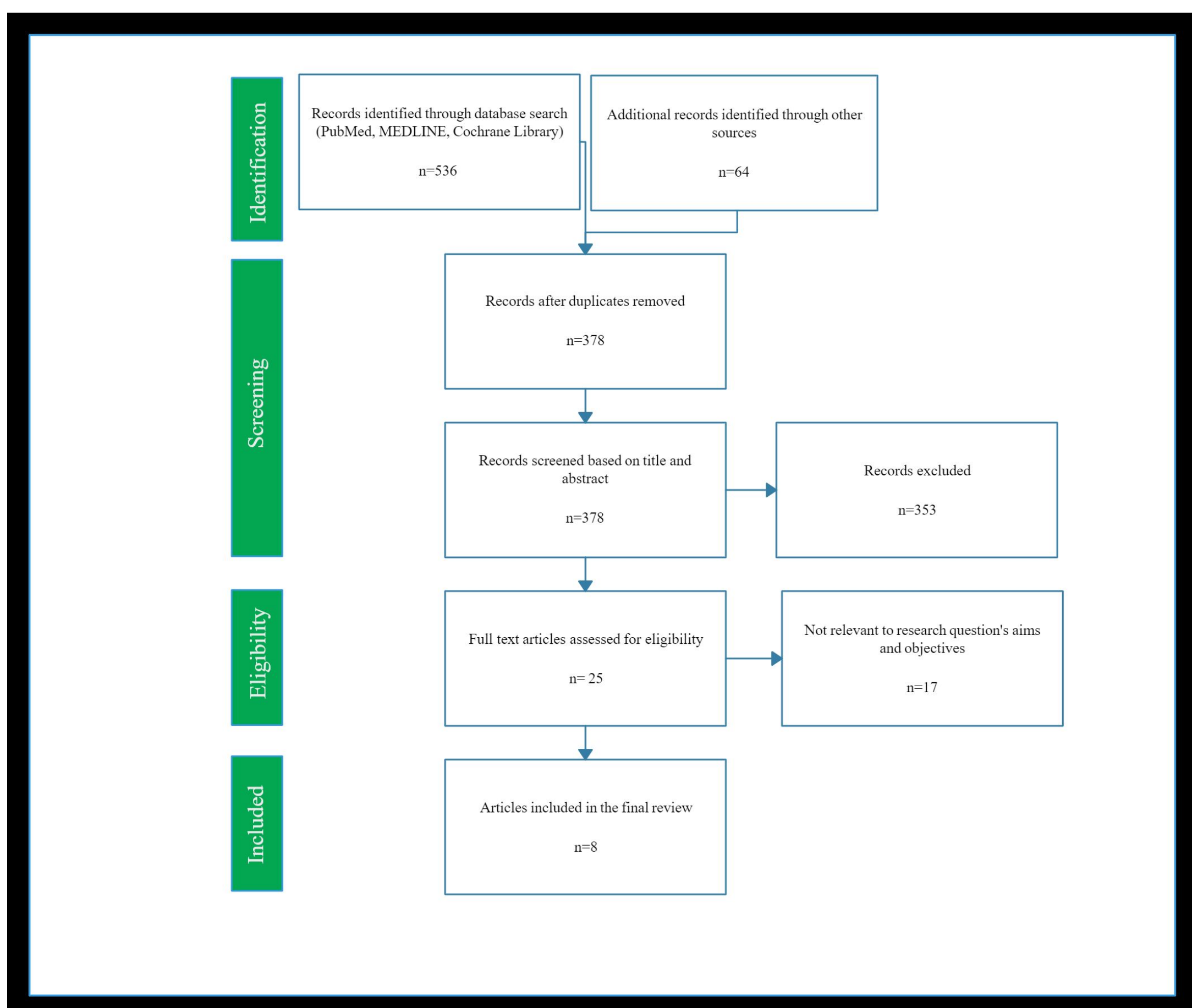


Figure 1. Diagram of article selection process.

## Introduction & Review:

Comminuted fractures of the tibial plafond are difficult to treat mainly due to associated soft-tissue injury and high-energy fracture patterns<sup>1</sup>. These fractures account for approximately 1% of all lower extremity fractures and 5 to 10% of tibial fractures<sup>2,3</sup>. The complexity of these fractures is often a result of the high-energy nature of the injury and the mechanism of axial compression with components of shear and bending forces<sup>1,2,4,5,6</sup>. Various treatment methods have been proposed throughout the literature with no consensus on a gold standard method of treatment for these fractures. Open reduction internal fixation (ORIF) has historically been utilized as the preferred treatment method, as restoration of the anatomic surface of the ankle has been the most important belief in reducing long term postoperative arthritic conditions<sup>7,8,9</sup>. However, various studies have documented high rates of infection, wound dehiscence, arthrodesis and overall complications. It is proposed that these high complication rates could be attributed as a result of insult to the soft tissue<sup>11,12,13</sup>.

Alternatively, external fixation with limited internal fixation (EFLIF) was proposed as a method to reduce soft tissue compromise by limiting the need for excessive incisions and surgical dissection, which can result in damage to the underlying tissue<sup>2,3,7</sup>. Theoretically, this method would also provide reduction of the articular surface, and with the addition of the limited internal fixation should further reduce the surface anatomically. Literature has been unclear thus far favoring one method over the other.

## Results:

- In total 8 articles were included in the final data analysis:
  - Total fractures = 440
  - ORIF = 255 fractures
  - EFLIF = 185 fractures
- Quality and Level of Evidence
  - 5 Retrospective studies
  - 3 Prospective studies
  - Level of evidence 2 = 3 studies
  - Level of evidence 3 = 5 studies
- Comparative results across studies regarding EFLIF vs ORIF, with slightly less complications achieved with ORIF
- Postoperative Findings
  - Significantly increased rate of superficial infection in the EFLIF group (4.71% ORIF vs 17.84% EFLIF)
  - Significantly increased rate of malunion (5.49% ORIF vs 12.43% EFLIF) and significantly decreased incidence of union (91.37% ORIF vs 82.16% EFLIF) in the EFLIF group
  - No difference in arthrosis, nonunions, rates of deep infection and occurrence of osteomyelitis

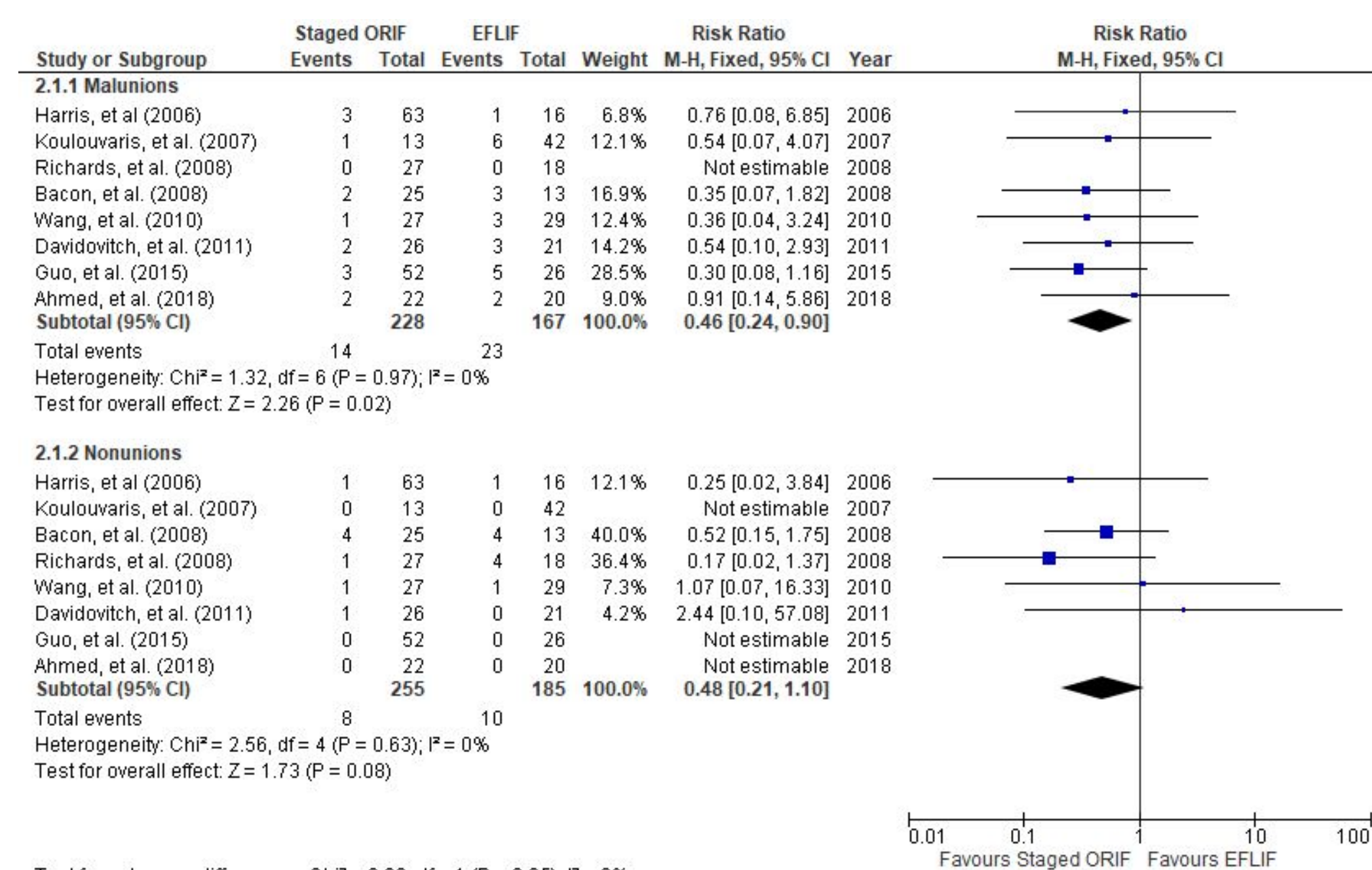


Figure 2. Forest plot of Staged ORIF vs EFLIF for the subgroups of malunions and nonunions

## Results Continued:

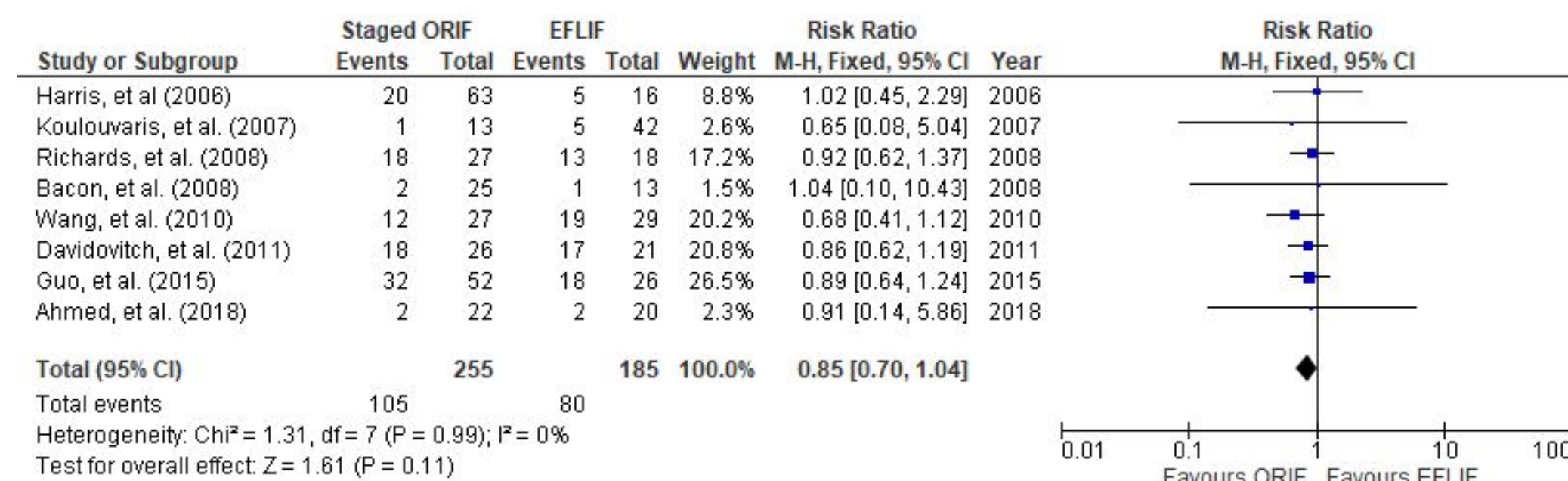


Figure 3. Forest plot of Staged ORIF vs EFLIF for the subgroup of Arthritic ankle joint changes

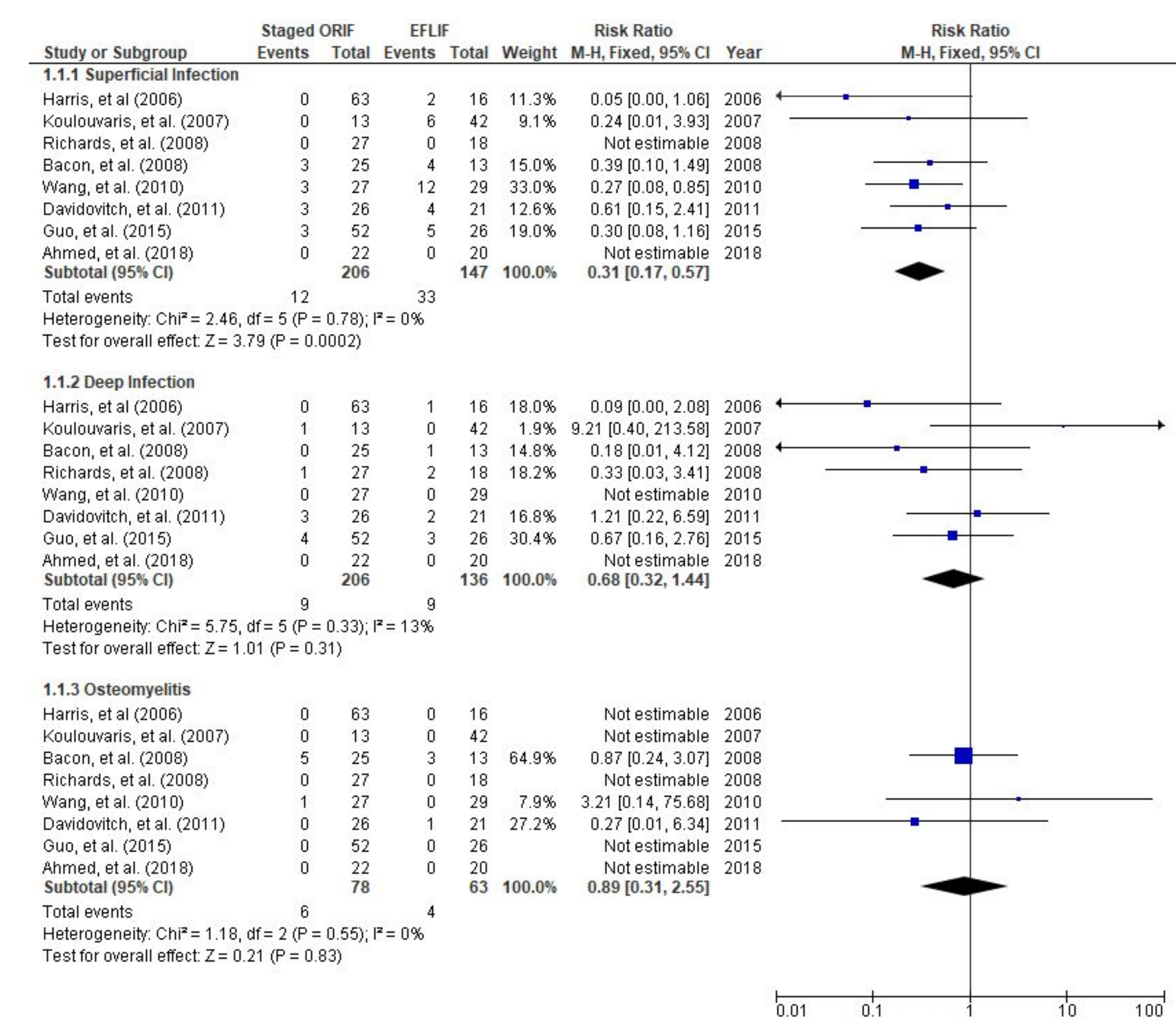


Figure 4. Forest plot of Staged ORIF vs EFLIF for the subgroups of superficial infection, deep infection, and Osteomyelitis

Postoperative Complications	Staged ORIF (rate of complications)	EFLIF (rate of complications)	p-value
Superficial Infection	12/255 (4.71%)	33/185 (17.84%)	<b>0.0002</b>
Deep Infection	9/255 (3.53%)	9/185 (4.86%)	0.31
Osteomyelitis	6/255 (2.35%)	4/185 (2.16%)	0.83
Time to union (wks)	24.39 +/- 7.78	23.35 +/- 4.75	0.78
Nonunion	8/255 (3.12%)	10/255 (5.40%)	0.08
Malunion	14/255 (5.49%)	23/255 (12.43%)	<b>0.02</b>
Fracture union	233/255 (91.37%)	152/255 (82.16%)	<b>0.002</b>
Ankle joint arthrosis	105/255 (41.16%)	86/255 (46.49%)	0.11

Figure 5. Table of summary of postoperative findings regarding ORIF vs EFLIF

## Discussion:

Tibial pilon fractures are severe injuries with a multitude of complications. Causes of pilon fractures can include motor vehicle crashes, falls from height, and similar traumatic high energy mechanisms of injury. The high axial load and torsion of these injuries not only contributes to tibial plafond destruction but also results in severe soft tissue trauma. Thus, the mechanism of repairing Pilon fractures with preservation of the underlying soft tissue envelope remains challenging. Treatments of the injury have evolved over time but there remains no gold standard for surgeons to follow.

Our current meta-analysis sought to compare the postoperative outcomes of two deferring fixation methods: ORIF and EFLIF. Our current study demonstrated a statistically significant increased risk of superficial infection in the EFLIF group (I<sup>2</sup> = 0%, p = 0.0004). This result was expected as the usage of hardware with contact to the external surface creates a direct route of introduction for pathogens. However, no difference was noted in deep infection rates between the groups. These findings were supported by Meng et al.<sup>8</sup>, but were contradicted by Cui et al. and Wang et al. in their respective meta-analyses

The meta-analysis also showed a statistically significant increased risk of malunions in the EFLIF group (I<sup>2</sup> = 0%, p = 0.02). Again, this result was supported by Meng et al.<sup>8</sup>, but was contradicted by Cui et al. and Wang et al. in their respective meta-analyses. Finally, there was a statistically significant lower incidence of boney union in the EFLIF group (p = 0.002). Previous meta-analyses have hypothesized that this decreased union and increased rate of malunion may be secondary to a lack of anatomic reduction which can be more easily obtainable with ORIF.

## Conclusion:

Pilon fractures, especially those of the type 43C variety, are complex injuries requiring meticulous planning and management. Both EFLIF and ORIF are viable options, and the decision of which method to utilize should be based on physician's preference, familiarity with the equipment, knowledge of the planned procedure, and the presentation of the fracture. The results of this investigation show that an ORIF approach for fixation does have some benefits in regards to reducing rates of superficial infections and malunions, as well as improving overall rate of unions.

## References:

- Bacon S, Smith WR, Morgan SJ, et al. A retrospective analysis of comminuted intra-articular fractures of the tibial plafond: Open reduction and internal fixation versus external Ilizarov fixation. *Injury*. 2008;39(2):196-202. doi:10.1016/j.injury.2007.09.003
- Guo, Y, Tong, L, Li, S, Liu, Z. External fixation combined with limited internal fixation versus open reduction internal fixation for treating Rüedi-Allgöwer Type III Pilon fractures. *Med Sci Monit* 2015;21: 1662-7. https://doi.org/10.12659/MSM.893289
- Koulovaris P, Stafylas K, Mitsionis G, Vekris M, Mavrodontidis A, Xenakis T (2007) Long-term results of various therapy concepts in severe pilon fractures. *Arch Orthop Trauma Surg* 127(5):313-320
- Davidovitch RI, Elkhechen RJ, Romo S et al: Open reduction with internal fixation versus limited internal fixation and external fixation for high grade pilon fractures (OTA type 43C). *Foot Ankle Int*, 2011; 32: 955-61
- Harris AM, Patterson BM, Sontich JK, Vallier HA. Results and outcomes after operative treatment of high-energy tibial plafond fractures. *Foot Ankle Int*. 2006; 27:256-265
- Wang D, Xiang J-P, Chen X-H, Zhu Q-T. A Meta-Analysis for Postoperative Complications in Tibial Pilon Fracture: Open Reduction and Internal Fixation Versus Limited Internal Fixation Combined With External Fixation. *The Journal of Foot and Ankle Surgery*. 2015;54(4):646-651. doi:10.1053/j.jfas.2014.06.007
- Luo TD, Pilon H. Pilon Fracture. [Updated 2020 Jan 21]. In: StatPearls [Internet]. Treasure Island (FL): StatPearls Publishing; 2020 Jan-. Available from: <https://www.ncbi.nlm.nih.gov/books/NBK482176/>
- Meng Y-C, Zhou X-H. External fixation versus open reduction and internal fixation for tibial pilon fractures: A meta-analysis based on observational studies. *Chinese Journal of Traumatology*. 2016; 19(5):278-282. doi:10.1016/j.cjtee.2016.06.002
- Ruedi TP, Allgöwer M: Fractures of the lower end of the tibia into the ankle joint. *Injury*. 1:92-99, 1969
- Sirkkin M, Sanders R, DiPasquale T, Herscovici D Jr. A staged protocol for soft tissue management in the treatment of complex pilon fractures. *J Orthop Trauma*. 1999; 13:78-84.
- Bourne RB, Rorabeck CH, Macnab J. Intra-articular fractures of the distal tibia: the tibial pilon fracture. *J. Trauma*. 23:591-596, 1983
- Teeny SM, Weiss DA: Open reduction and internal fixation of tibial plafond fractures. Variables contributing to poor results and complications. *Clin. Orthop*. 292:108-117, 1993.
- Wyrsch B, McFerran MA, McAndrew M, et al.: Operative treatment of fractures of the tibial plafond. A randomized prospective study. *J. Bone Joint Surg*. 78-A:1646-1657, 1996.
- Cui X, Chen H, Rui Y, Niu Y, Li H. Two-stage open reduction and internal fixation versus limited internal fixation combined with external fixation: a meta-analysis of postoperative complications in patients with severe Pilon fractures. *Journal of International Medical Research*. 2018;46(7):2525-2536. doi:10.1177/0300060518776099
- Ruedi TP, Allgöwer M: The operative treatment of intra-articular fractures of the lower end of the tibia. *Clin. Orthop*. 138:105-110, 1979.
- Dillin L, Slabaugh P. Delayed wound healing, infection, and nonunion following open reduction and internal fixation of tibial plafond fractures. *J Trauma* 26:1116-1119, 1986.
- Wang C, Li Y, Huang L, Wang M. Comparison of two-staged ORIF and limited internal fixation with external fixator for closed tibial plafond fractures. *Archives of Orthopaedic and Trauma Surgery*. 2010;130(10):1289-1297. doi:10.1007/s00402-010-1075-6
- Griffiths, GP; Thordarson, DB: Tibial plafond fractures: Limited internal fixation and a hybrid external fixator. *Foot Ankle Int*. 17:444-448, 1996.
- Rayan A, Kotb A, Elmoatass EM, et al. Open reduction internal fixation versus external fixation with limited internal fixation for displaced comminuted closed pilon fractures: A randomised prospective study. *Journal of Orthopaedics, Trauma and Rehabilitation*. 2018;24:84-89. doi:10.1016/j.jotr.2017.08.001
- Richards, J. E., Magill, M., Tressler, M. A., Shuler, F. D., Kregor, P. J., & Obrebsky, W. T. (2012). External Fixation Versus ORIF for Distal Intra-articular Tibia Fractures. *Orthopedics*, 35(6). doi: 10.3928/01477447-20120525-25