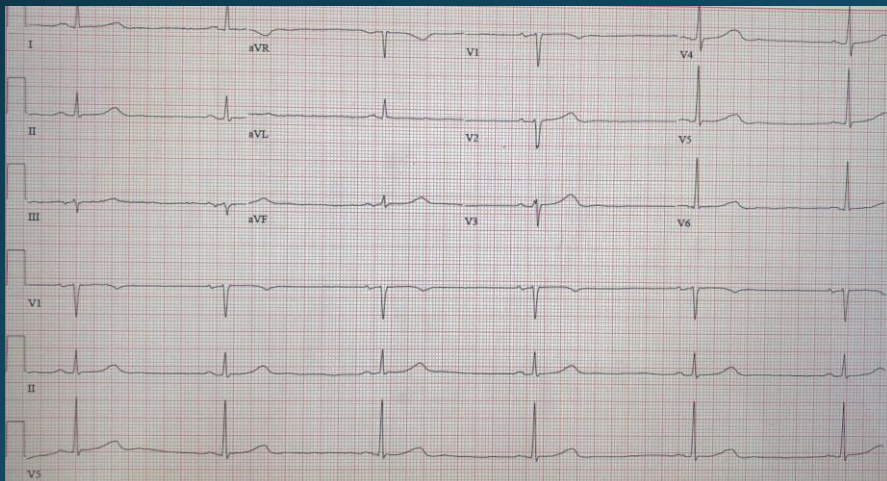


# Bradyarrhythmias in Obstructive Sleep Apnea

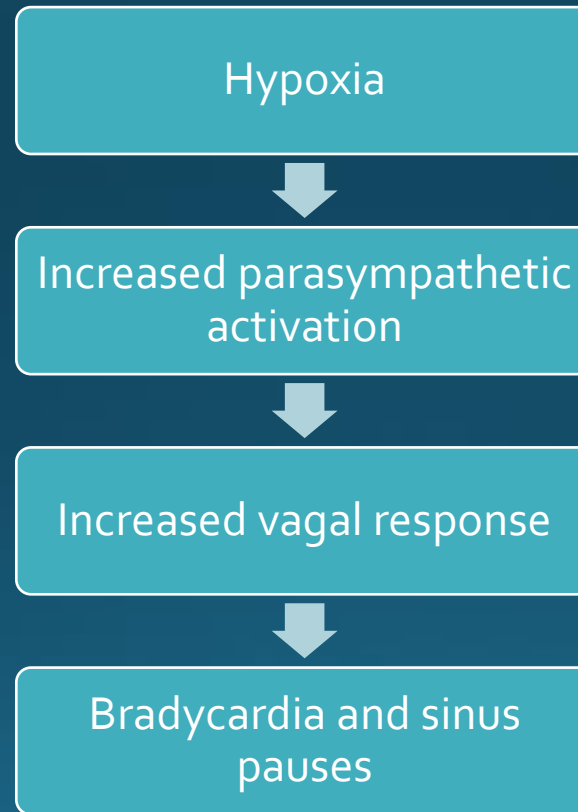
Lauren Sesemann DO

- 74-year-old male with pmhx of HTN, HLD, paroxysmal atrial fibrillation, OSA noncompliant with CPAP admitted for urosepsis, pneumonia and atrial fibrillation with RVR
- Atrial fibrillation responded well to metoprolol tartrate, but was discontinued due to nocturnal and intermittent episodes of bradycardia
- Bradycardia noted only while sleeping at night and during the day without CPAP



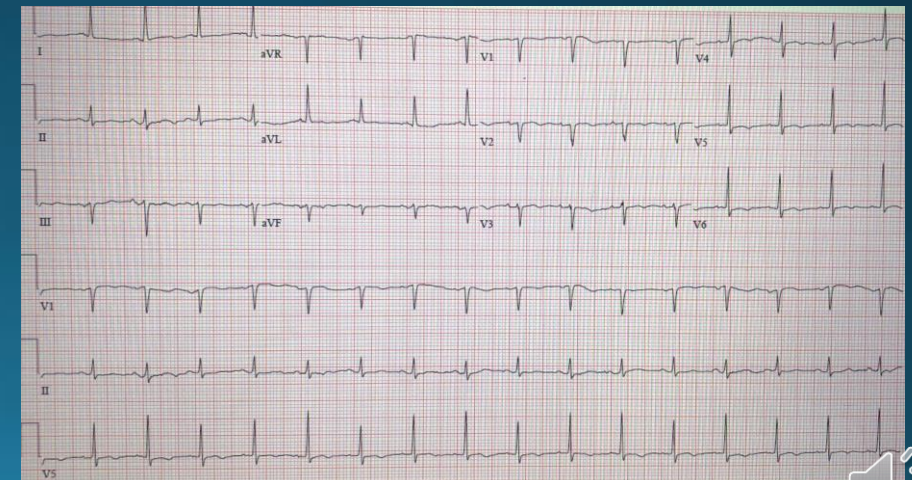
While sleeping without CPAP

## Proposed Mechanism



## Treatment

- Strict adherence with CPAP while sleeping
- For severe symptomatic bradycardia and sinus pauses, cardiology evaluation for possible pacemaker



Sleeping with CPAP and beta blocker

