Transmetatarsal Amputations - Outcomes of Primary Healing vs. Secondary Healing

Clare Cormier, DPM; Zach Janes, DPM; Yelena Boumendjel, DPM; John Grady, DPM

Department of Podiatry, Advocate Christ Medical Center

Advocate Christ Medical Center
Tomorrow starts today.

Statement of Purpose:

The aim of this study is to determine if primary closure of a transmetatarsal amputation (picture 1) is an acceptable treatment option for treatment of forefoot infection, dry gangrene, and/or chronic ulceration. We hypothesize that primary closure of a TMA is as effective of a treatment method as a secondary wound closure of a TMA after forefoot infection, dry gangrene and/or chronic ulceration.

Introduction:

Transmetatarsal amputations (TMA) are limb salvage surgical procedures that preserve limb length and functional ankle joints.[1] Indications for TMAs include forefoot trauma, infection, and ischemia. Prior research demonstrates patients who undergo TMAs have a lower 2-year mortality rate compared to those who undergo below-the-knee amputations (BKAs).[1,2] Additionally, it has been found that patient selection for TMA is critical for increasing the chances of surgical site healing. Important factors to be evaluated prior to TMA surgery include vascular status and adequate soft tissue coverage.[1,3,4,5] Traditionally, TMAs are performed as staged procedures with an initial period of leaving the surgical site open, especially after infection [6,7]; however, research has shown that after thorough surgical debridement with adequate control of infection and clean margins present at the wound site, primary closure of the amputation site is appropriate.[8,9] The controversy between primary closure of TMAs versus secondary healing of TMAs is ongoing. Some researchers argue that primary closure can help to decrease healing time and the need for additional surgery.[8,10] Nevertheless, other investigators have stressed that recurrent infection rate is higher in TMAs that are closed primarily.[7] Furthermore, the literature investigating primary closure versus staged closure partial foot amputations is scarce and a conclusion has yet to be reached. Even less literature has specifically looked at primary closure versus healing by secondary intention of TMAs.

Picture 1: Closed TMA surgical site, post-op day 1.

Methodology:

- **Study Population:**
  - Retrospective chart review was performed on patients of Foot and Ankle Associates, Ltd., from September 2011 through December 2019.
  - Patients selected through an electronic medical record search of current procedural terminology (CPT) code 28805.
  - **Inclusion criteria:** (1) Patients 18+ years of age (2) requiring a transmetatarsal amputation due to forefoot infection, gangrene and/or chronic ulceration.
  - **Exclusion criteria:** (1) patients with a prior complete ray amputation to the ipsilateral foot as the TMA, (2) a preoperative diagnosis of wet-gangrene and/or (3) necrotizing fasciitis, and (4) those patients that were lost to follow up before documented healing of the TMA surgical site.
- **Operative Procedures:**
  - All operations were performed by board qualified foot and ankle surgeons if a TMA was required for a patient due to forefoot gangrene, infection, and/or chronic ulceration.
  - Operative principles included aggressive debridement of all nonviable soft tissue and bone, wide drainage of purulent collections, and performance of TMAs.
  - Wound closure was judged and decided upon clinically by attending surgeon
    - 1. primary closure of TMA (group 1)
    - 2. Secondary intention healing of TMA (group 2)
- **Data Collection and Follow Up:**
  - All patients were monitored postoperatively in an outpatient clinic staffed by Foot and Ankle Associates, Ltd. foot and ankle surgeons.
  - Wound healing measurements were based on medical record physical exam documentation.
  - Variables measured included healing time of TMA site, recurrent infection, recurrent gangrene, wound dehiscence, revisional surgery, more proximal amputations such as below-the-knee amputation (BKA) and above-the-knee amputation (AKA), and death.
- **Statistical Analysis:**
  - Sample size was of convenience. The comparison of demographic data was done using chi-squared or Fisher's exact test. A 5% significance level or the corresponding P value was used in all tests. All analyses were performed using SPSS.

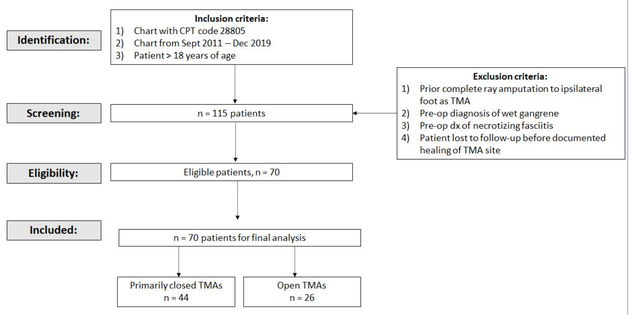

Figure 1. Collection and screening of patients for final analysis.

Results:

- Medical records of 115 patients who underwent TMAs between September 2011 through July 2019 were analyzed
  - 70 total patients included for final review (Figure 1) with two groups:
    - Group 1, closed TMAs, yielded 44 patients
    - Group 2, open TMAs, yielded 26 patients
- Overall healing rates:
  - Group 1, closed TMAs (n = 44) overall healing rate of 75% (33/44)
  - Group 2, open TMAs (n = 26) healing rate of 50% (13/26)
  - A chi-square analysis showed a statistically significant greater incidence of healing for closed TMAs compared to open TMAs (X^2 [1, N = 70] = 4.53, $p = 0.03$)
- Recurrent gangrene rate
  - Closed TMAs - 11.1%
  - Open TMAs - 34.6%.
  - A chi-square analysis was completed and the results indicated closed TMAs are statistically significantly less likely than open TMAs to experience recurrent gangrene (X^2 [1, N = 70] = 7.04, p = 0.01).
- Median healing times
  - Closed TMAs - 16 weeks (range = 6.0-25.0 weeks)
  - Open TMAs - 22 weeks (range = 8.0-36.0 weeks).
- Recurrent infection rate
  - Closed TMAs - 2.9%
  - Open TMAs -15.4%.
- Revisional TMA surgery rate
  - Closed TMAs - 9.1%
  - Open TMAs - 15.4%
- Progression to more proximal amputation
  - Closed TMAs - 20.5%
  - Open TMAs - 50%.

	Closed TMAs (N=44)	Open TMAs (n=26)	p-value
Healing Status			
Healed	33 (75%)	13 (50%)	0.03*
Failed	11 (25%)	13 (50%)	
Complications			
Infection	1 (2.9%)	4 (15.4%)	0.06
Recurrent gangrene	4 (11.1%)	9 (34.6%)	0.01*
Revisional TMA surgery	4 (9.1%)	4 (15.4%)	0.46
BKA	8 (18.2%)	13 (50%)	0.01
AKA	1 (2.3%)	0 (0%)	1.00
Death	2 (4.6%)	2 (7.7%)	0.62
Healing time			
Weeks - median (IQR)	16 (6.0-25.0)	22 (8.0-36.0)	0.22

*Statistically significant

Table 1: Open versus Closed TMAs Healing Status and Complications.

Discussion:

TMAs are important, life-saving procedures. Mayfield et al. (2001) demonstrated that limb-salvage amputations such as TMAs, Lisfranc's, and Chopart's amputations yield a 28% higher 2-year survival rate than those who undergo BKAs. Our research investigated whether primary closure of a TMA is an acceptable treatment option for treatment of forefoot infection, dry gangrene, and/or chronic ulceration.

Our study found that primary closure of TMA surgical sites is an appropriate surgical treatment option following forefoot infection, dry gangrene, and/or chronic ulceration. Prior studies have recommended that TMA's should be performed as a staged procedure or remain open and to heal by secondary intention. [6,7,11] Our data shows that primarily closed TMAs have a statistically significantly greater chance of healing than TMAs that are left to heal by secondary intention. Furthermore, TMAs closed primarily yield a 75% overall healing rate compared to only 50% healing rate in those TMAs left open. Landry et al. (2011) found a similar high rate of healing of 67% with primarily closed TMAs. Additionally, Anthony et al. (2006) found that primarily closed TMAs had a higher rate of healing of 84% compared with open TMAs that had a lower healing rate of 57%. These studies, along with our data, strengthen the argument that if patients meet the criteria of appropriate vascular healing potential, viable skin flaps, and eradication of infection, primary closure of amputation sites improves healing potential and may shorten healing time. Shorter healing time may reduce wound care costs, the non-weight bearing period for the patients, and the rate of recurrent infection. [5,9,10,12,13]

Our study also revealed a statistically significant lower recurrent gangrene rate in the closed TMA group compared to the open TMA group. A decreased rate of recurrent gangrene in closed TMAs versus open TMAs demonstrates that primary closure of TMAs does not lead to strangulation of tissue or further necrosis. This finding strengthens the argument that primary closure of TMAs is an appropriate treatment option for midfoot amputation. Our findings demonstrate that primary closure of TMAs is not only an effective treatment option, but has superior healing percentages and potential when compared to open TMAs.

Conclusion:

In conclusion, our research demonstrated that primary closure of TMAs is as effective a treatment option as secondary wound closure of a transmetatarsal amputation due to infection, dry gangrene and/or chronic ulceration. Furthermore, our data demonstrates that after thorough debridement of infection, primarily closed TMAs may be a superior treatment modality to staged or open TMAs and offer the patient a better chance of healing and decreased risk of complications in the postoperative period.

Acknowledgements:
Special thanks to Nicole Glowacki, MPH, for her help with the statistical analysis.

References:

1. Attinger CE, Brown BJ. Amputation and ambulation in diabetic patients: function is the goal. *Diabetes/Metabolism Research & Reviews*. 2012;28:93-96. doi:10.1002/dmrr.2236.
2. Mayfield JA, Reiber GE, Maynard C, Czerniecki JM, Caps MT, Sangeorzan BJ. Survival following lower-limb amputation in a veteran population. *Journal of Rehabilitation Research & Development*. 2001;38(3):341-345. https://search-ebscohost-com.ezproxy.rosalindfranklin.edu/login.aspx?direct=true&db=ccm&AN=106947426&site=eds-live&scope=site. Accessed January 20, 2020.
3. Barshes NR, Bechara CF, Pisimisis G, Kougias P. Preliminary experiences with early primary closure of foot wounds after lower extremity revascularization. *Annals Of Vascular Surgery*. 2014;28(1):48-52. doi:10.1016/j.avsg.2013.06.012
4. Lakstein D, Feldbrin Z, Schorr L, Lipkin A. Primary closure of elective toe amputations in the diabetic foot--is it safe? *Journal Of The American Podiatric Medical Association*. 2014;104(4):383-386. doi:10.7547/0003-0538-104.4.383.
5. Nehler MR, Whitehill TA, Bowers SP, et al. Intermediate-term outcome of primary digit amputations in patients with diabetes mellitus who have forefoot sepsis requiring hospitalization and presumed adequate circulatory status. *Journal Of Vascular Surgery*. 1999;30(3):509-517. https://search-ebscohost-com.ezproxy.rosalindfranklin.edu/login.aspx?direct=true&db=cmedm&AN=10477644&site=eds-live&scope=site. Accessed December 28, 2019.
6. Durham JR, McCoy DM, Sawchuk AP, et al. Open transmetatarsal amputation in the treatment of severe foot infections. *American journal of surgery*. 1989;158(2):127-130. https://search-ebscohost-com.ezproxy.rosalindfranklin.edu/login.aspx?direct=true&db=cmedm&AN=2757139&site=eds-live&scope=site. Accessed May 9, 2020.
7. Senkowsky J, Money MK, Kerstein MD. Lower Extremity Amputation: Open Versus Closed. *Angiology*. 1990;41(3):221. https://search-ebscohost-com.ezproxy.rosalindfranklin.edu/login.aspx?direct=true&db=edb&AN=16352631&site=eds-live&scope=site. Accessed December 27, 2019.
8. Bercell SA, Brown JE, Irwin PB, Ozaki CK. Clinical outcomes after closed, staged, and open forefoot amputations. *Journal of Vascular Surgery*. 2006;44(2):347. https://search-ebscohost-com.ezproxy.rosalindfranklin.edu/login.aspx?direct=true&db=edo&AN=23067809&site=eds-live&scope=site. Accessed December 27, 2019.
9. Blume PA, Paragas LK, Sumpio BE, Attinger CE. Single-stage surgical treatment of noninfected diabetic foot ulcers. *Plastic And Reconstructive Surgery*. 2002;109(2):601-609. https://search-ebscohost-com.ezproxy.rosalindfranklin.edu/login.aspx?direct=true&db=cmedm&AN=11818842&site=eds-live&scope=site. Accessed December 27, 2019.
10. Aerden D, Vanmierlo B, Denecker N, Brasseur L, Keymeulen B, Van den Brande P. Primary closure with a filleted hallux flap after transmetatarsal amputation of the big toe for osteomyelitis in the diabetic foot: a short series of four cases. The International Journal Of Lower Extremity Wounds. 2012;11(2):80-84. doi:10.1177/1534734612446640.
11. Silva LR, Fernandes GM, Morales NU, et al. Results of One-Stage or Staged Amputations of Lower Limbs Consequent to Critical Limb Ischemia and Infection. *Annals Of Vascular Surgery*. 2018;46:218-225. doi:10.1016/j.avsg.2017.06.144.
12. Hunt NA, Liu GT, Lavery LA, Resendez R. The Economics of Limb Salvage in Diabetes. *Foot & Ankle Quarterly--The Seminar Journal*. 2016;27(1):7-10. https://search-ebscohost-com.ezproxy.rosalindfranklin.edu/login.aspx?direct=true&db=ccm&AN=114503316&site=eds-live&scope=site. Accessed January 12, 2020.
13. Anthony T, Roberts J, Modrall JG, et al. Transmetatarsal amputation: assessment of current selection criteria. *American journal of surgery*. 2006;192(5):e8-e11. https://search-ebscohost-com.ezproxy.rosalindfranklin.edu/login.aspx?direct=true&db=cmedm&AN=17071183&site=eds-live&scope=site. Accessed January 10, 2020.